

Kidney Biopsy Should Be Performed to Document the Cause of Immune Checkpoint Inhibitor–Associated Acute Kidney Injury: Commentary

Mark A. Perazella^{1,2}

KIDNEY360 1: 166–168, 2020. doi: <https://doi.org/10.34067/KID.0001072019>

The debate in this issue of *Kidney360* involves the role of kidney biopsy in patients with cancer who develop AKI while receiving immune checkpoint inhibitors (ICPIs). The question is whether we need kidney tissue to diagnose the cause of AKI and guide management in these patients. Two expert onconephrologists, Ben Sprangers and Ilya Glezerman, present the pro and con sides of the debate, respectively. I will provide background on the ICPIs and their associated nephrotoxicity to lay the groundwork for the debate.

The ICPIs are humanized mAbs against host immune checkpoints (CTLA-4 and PD-1 receptors and PD ligand-1) that are used to treat a number of different cancers. By attenuating the inhibitory effects of immune checkpoints on T cells, other immune cells, and cancer cells, these agents allow eradication of tumors that would otherwise evade immune destruction (1–5). Although the ICPIs have greatly improved cancer therapy, immune-related adverse drug effects complicate their course (6,7). Extrarenal complications occur relatively commonly; however, drug nephrotoxicity is also observed (7–9). In review articles containing published biopsy-proven cases, acute tubulointerstitial nephritis (ATIN) is most common (51 of 90; 57%), whereas acute tubular injury (ATI; $n=13$), various glomerulopathies ($n=20$), and other kidney lesions ($n=6$) have also been described (7–10). In addition, patients with cancer also develop AKI that is unrelated to the ICPI-related toxicity. These include AKI from ischemic and/or nephrotoxic tubular injury, various drug- or cancer-related glomerular injuries, crystalline nephropathy, paraneoplastic kidney damage, and urinary obstruction. As such, patients with cancer who develop AKI during ICPI therapy should be carefully evaluated to correctly diagnose the kidney lesion and guide appropriate management (8–10).

Nephrologists generally use kidney biopsy to obtain diagnostic information for AKI of unclear etiology, rapidly progressive GN, and nephritic/nephrotic syndrome. However, biopsy is not pursued when the cause of AKI is clinically obvious. Examples include AKI that develops in settings such as hypotension/shock, acute decompensated heart failure, hepatorenal syndrome, or exposure to a known nephrotoxin. A

controversial area for kidney biopsy is in the evaluation of ATIN. Many clinicians believe that clinical suspicion along with supporting laboratory data (e.g., eosinophilia, sterile pyuria, etc.) is sufficient to make a diagnosis. In contrast, others believe that, in most patients, ATIN can only be diagnosed with kidney biopsy. In reality, however, the touted clinical and laboratory findings indicative of ATIN may be absent in many patients with biopsy-proven ATIN (11,12). Despite this well known limitation, many clinicians continue to diagnose and treat ATIN without confirmatory kidney biopsy.

It seems that the same noninvasive approach to ATIN diagnosis has spilled over to ICPI-associated AKI. A recent publication noting only one kidney biopsy in 169 patients who developed ICPI-associated AKI corroborates this approach (13). Published data on ICPI-associated AKI suggest that, like other forms of drug-induced ATIN, clinical findings and laboratory tests poorly predict the underlying kidney lesion (7–10). In addition, the presence or absence of extrarenal immune-related end organ injury is not helpful in predicting ICPI-associated ATIN. For example, less than half of patients with a documented kidney lesion had another extrarenal immune-related end organ manifestation (9). Currently, the correct approach to making a diagnosis is debated.

In this *Kidney360* debate, Drs. Sprangers and Glezerman provide the pro and con arguments, respectively, on the need for kidney biopsy in the setting of ICPI-associated nephrotoxicity (Figure 1). Dr. Sprangers states that kidney biopsy should be obtained because patients with cancer on ICPIs who develop AKI may have ATI and other kidney lesions rather than ATIN. Identification of non-ATIN kidney lesions, such as ATI, allows avoidance of corticosteroid exposure and potential continued ICPI therapy. He argues that assuming that patients have ATIN may expose them to unnecessary corticosteroids (with their associated complications) and lead to ill-advised ICPI discontinuation. This approach may ultimately lead to inferior cancer treatment outcomes. In contrast, Dr. Glezerman argues that a recent, multicenter study on ICPIs noted biopsy-proven ATIN in 93% of patients with AKI, providing

¹Department of Medicine, Section of Nephrology, Yale University School of Medicine, New Haven, Connecticut; and ²Section of Nephrology, Veterans Affairs Connecticut Medical Center, West Haven, Connecticut

Correspondence: Mark A. Perazella, Yale University School of Medicine, 330 Cedar Street, New Haven, CT 06705. Email: Mark.perazella@yale.edu

evidence that, in most cases, AKI can be correctly assumed to be due to ATIN (14). However, more than half of the patients with AKI in this large series did not undergo biopsy, making it possible that these patients had a different lesion. Dr. Glezerman also argues that, because 87% of patients had either complete or incomplete kidney recovery following corticosteroid therapy, this positive response makes biopsy unlikely to modify therapy when empirical corticosteroids are so beneficial. However, because 43% of the corticosteroid-treated patients had only incomplete kidney recovery, two explanations are possible. One supports the pro biopsy argument that not all of these patients actually had ATIN. The other supports the con argument that not all corticosteroid-treated ATIN completely recovers. However, it is important to remember that recovery from AKI in the nonbiopsied patients may just reflect the natural course of ATI recovery and have nothing to do with corticosteroids, making the argument that kidney recovery in patients getting corticosteroids is indicative of ATIN incorrect.

In the spirit of full disclosure, I must admit that I am in the pro kidney biopsy camp (15). As such, I agree with Dr. Sprangers that knowing the type of kidney lesion matters because drug withdrawal and/or corticosteroids may be required for patients with ATIN, but neither is required for ATI and other nonimmune-mediated lesions. This would

spare patients unnecessary corticosteroid exposure and potentially allow continued ICPI administration unless other immune-related organ involvement is present. In my opinion, a useful rule of thumb is that treatment with corticosteroids should rarely be pursued empirically in many patients. Thus, accurate diagnosis is key. However, as Dr. Glezerman points out, one can take the approach that most ICPI-associated AKI will be ATIN and that empirical corticosteroids will result in complete or incomplete recovery in the majority of patients without risking kidney biopsy complications. This point is particularly relevant for patients at high risk for a biopsy complication (thrombocytopenia or coagulopathy) and those with a single kidney. Many oncologists believe that an empirical course of corticosteroids is low risk for these patients, and they currently recommend this approach in their guidelines (16). One can argue that this approach is reasonable in patients who have another immune-mediated organ injury, avoiding the potential complications of kidney biopsy.

What does the future hold for diagnosing ATIN in patients exposed to ICPIs? Novel urinary cytokine biomarkers IL-9 and TNF- α , which were recently shown to effectively distinguish ATIN from ATI and other kidney lesions (17), may be an option in the future. They represent a noninvasive test that may potentially identify ATIN in patients with cancer receiving ICPIs. Obviously, these

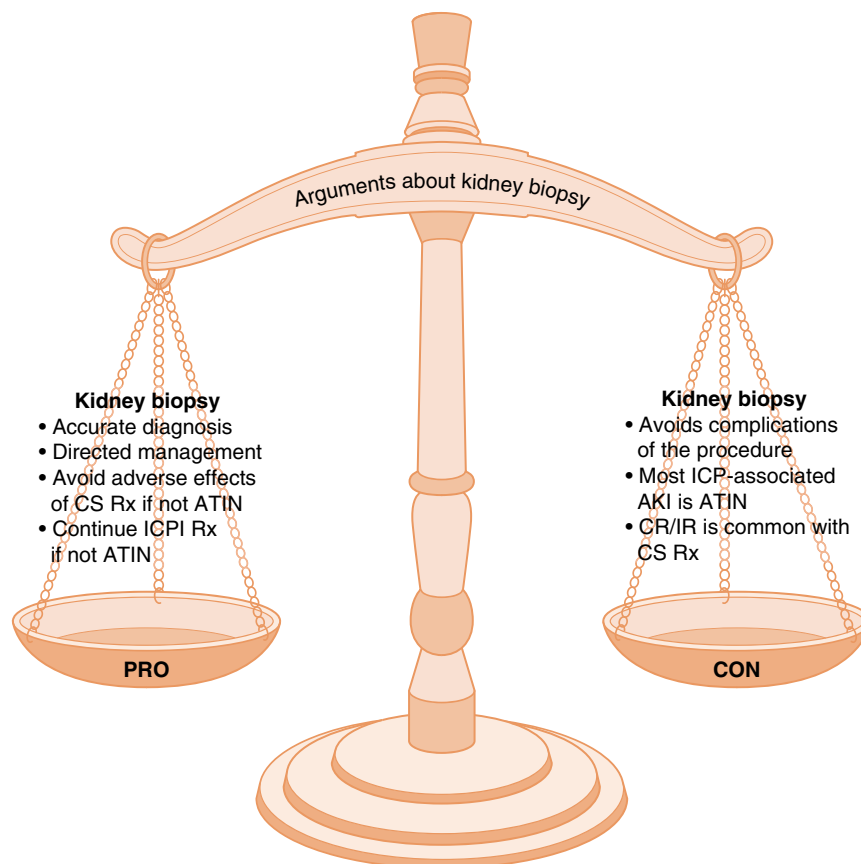


Figure 1. | Pro and con arguments about performing kidney biopsy in patients who develop AKI on immune checkpoint inhibitors. ATIN, acute tubulointerstitial nephritis; CR, complete remission; CS, corticosteroid; ICP, immune checkpoint; ICPI, immune checkpoint inhibitor; IR, incomplete remission; Rx, therapy.

urinary biomarkers must undergo rigorous testing to assess their diagnostic utility in this setting. In the meantime, onconephrologists must decide when to use kidney biopsy for AKI in patients receiving the ICPIs.

Author Contributions

M. Perazella conceptualized the study and wrote the original draft.

Disclosures

M. Perazella has nothing to disclose.

References

- Anari F, Ramamurthy C, Zibelman M: Impact of tumor micro-environment composition on therapeutic responses and clinical outcomes in cancer. *Future Oncol* 14: 1409–1421, 2018
- Yu Y, Cui J: Present and future of cancer immunotherapy: A tumor microenvironmental perspective. *Oncol Lett* 16: 4105–4113, 2018
- Leone P, Shin EC, Perosa F, Vacca A, Dammacco F, Racanelli V: MHC class I antigen processing and presenting machinery: Organization, function, and defects in tumor cells. *J Natl Cancer Inst* 105: 1172–1187, 2013
- Gatalica Z, Snyder C, Maney T, Ghazalpour A, Holterman DA, Xiao N, Overberg P, Rose I, Basu GD, Vranic S, Lynch HT, Von Hoff DD, Hamid O: Programmed cell death 1 (PD-1) and its ligand (PD-L1) in common cancers and their correlation with molecular cancer type. *Cancer Epidemiol Biomarkers Prev* 23: 2965–2970, 2014
- Lafuente-Sanchis A, Zúñiga Á, Estors M, Martínez-Hernández NJ, Cremades A, Cuenca M, Galbis JM: Association of PD-1, PD-L1, and CTLA-4 gene expression and clinicopathologic characteristics in patients with non-small-cell lung cancer. *Clin Lung Cancer* 18: e109–e116, 2017
- Postow MA, Sidlow R, Hellmann MD: Immune-related adverse events associated with immune checkpoint blockade. *N Engl J Med* 378: 158–168, 2018
- Perazella MA, Shirali AC: Nephrotoxicity of cancer immunotherapies: Past, present and future. *J Am Soc Nephrol* 29: 2039–2052, 2018
- Perazella MA, Shirali AC: Immune checkpoint inhibitor nephrotoxicity: What do we know and what should we do? *Kidney Int* 97: 62–74, 2020
- Sury K, Perazella MA, Shirali AC: Cardiorenal complications of immune checkpoint inhibitors. *Nat Rev Nephrol* 14: 571–588, 2018
- Cassol C, Satoskar A, Lozanski G, Rovin B, Hebert L, Nadasdy T, Brodsky SV: Anti-PD-1 immunotherapy may induce interstitial nephritis with increased tubular epithelial expression of PD-L1. *Kidney Int Rep* 4: 1152–1160, 2019
- Perazella MA, Markowitz GS: Drug-induced acute interstitial nephritis. *Nat Rev Nephrol* 6: 461–470, 2010
- Moledina DG, Perazella MA: Drug-induced acute interstitial nephritis. *Clin J Am Soc Nephrol* 12: 2046–2049, 2017
- Seethapathy H, Zhao S, Chute DF, Zubiri L, Oppong Y, Strohbahn I, Cortazar FB, Leaf DE, Mooradian MJ, Villani AC, Sullivan RJ, Reynolds K, Sise ME: The incidence, causes, and risk factors of acute kidney injury in patients receiving immune checkpoint inhibitors. *Clin J Am Soc Nephrol* 14: 1692–1700, 2019
- Cortazar FB, Kibbelaar ZA, Glezerman IG, Abudayyeh A, Mamlouk O, Motwani SS, Murakami N, Herrmann SM, Manohar S, Shirali AC, Kitchlu A, Shirazian S, Assal A, Vijayan A, Renaghan AD, Ortiz-Melo DI, Rangarajan S, Malik AB, Hogan JJ, Dinh AR, Shin DS, Marrone KA, Mithani Z, Johnson DB, Hosseini A, Uprety D, Sharma S, Gupta S, Reynolds KL, Sise ME, Leaf DE: Clinical features and outcomes of immune checkpoint inhibitor-associated AKI: A multicenter study. *J Am Soc Nephrol* 31: 435–446, 2020
- Perazella MA, Sprangers B: AKI in patients receiving immune checkpoint inhibitors. *Clin J Am Soc Nephrol* 14: 1077–1079, 2019
- Brahmer JR, Lacchetti C, Schneider BJ, Atkins MB, Brassil KJ, Caterino JM, Chau I, Ernstoff MS, Gardner JM, Ginex P, Hallmeyer S, Holter Chakrabarty J, Leighl NB, Mammen JS, McDermott DF, Naing A, Nastoupil LJ, Phillips T, Porter LD, Puzanov I, Reichner CA, Santomaso BD, Seigel C, Spira A, Suarez-Almazor ME, Wang Y, Weber JS, Wolchok JD, Thompson JA; National Comprehensive Cancer Network: Management of immune-related adverse events in patients treated with immune checkpoint inhibitor therapy: American Society of Clinical Oncology Clinical Practice Guideline. *J Clin Oncol* 36: 1714–1768, 2018
- Moledina DG, Wilson FP, Pober JS, Perazella MA, Singh N, Luciano RL, Obeid W, Lin H, Kuperman M, Moeckel GW, Kashgarian M, Cantley LG, Parikh CR: Urine TNF- α and IL-9 for clinical diagnosis of acute interstitial nephritis. *JCI Insight* 4: 127456, 2019

See related debates, “Kidney Biopsy Should Be Performed to Document the Cause of Immune Checkpoint Inhibitor-Associated Acute Kidney Injury: PRO” and “Kidney Biopsy Should Be Performed to Document the Cause of Immune Checkpoint Inhibitor-Associated Acute Kidney Injury: CON,” on pages 158–161 and 162–165, respectively.