

Severe Hypertension in a 3-Month-Old Infant

Jonathan Chawla,¹ David Manning,² and Isa Ashoor¹

KIDNEY360 1: 1464–1465, 2020. doi: <https://doi.org/10.34067/KID.0003602020>

Case Description

The patient is a 3-month-old male with known, mild, right-sided hydronephrosis secondary to ureteropelvic junction obstruction (UPJO), who presented to the emergency department with 1 week of poor feeding, episodic emesis, and abdominal distension. The family denied any change in urine output, but did affirm apparent discomfort when stooling, irritability, and grunting. In the emergency department, BP was 140/79 mm Hg in the right upper extremity. Laboratory workup was unremarkable: specifically, urinalysis was found to be free of blood and protein, with only 1+ leukocyte esterase and normal kidney function. Abdominal ultrasound revealed massive pelvocaliectasis of the right kidney, with the kidney parenchyma stretched and thinned over the massively dilated central collecting system (Figure 1). Findings were confirmed on the abdominal computed tomography scan, which also revealed the profound mass effect on the abdominal organs, vessels, and bowel, specifically compressing and displacing the aorta and inferior vena

cava (Figure 2, A and B). The contralateral kidney was found to have mild pelvocaliectasis, concerning for compression of the left ureter by the right collecting system. The patient was admitted to the pediatric intensive care unit for BP management, and this was effectively controlled with hydralazine. Antihypertensive medication was discontinued on hospital day 2 after the pediatric urology team placed a percutaneous nephrostomy tube and drained approximately 1 L of urine from the right collecting system. At time of discharge, no antihypertensive medications were prescribed, but the patient's laboratory test results were notable for mild hyperkalemia and nonanion gap metabolic acidosis, concerning for a type-4 renal tubular acidosis. The patient was scheduled for pyeloplasty shortly after discharge.

UPJO is the most common cause of antenatally detected hydronephrosis. The renal pelvis of infants exhibits increased compliance and can accommodate large urine volumes, as seen in this case. This may cause progressive deterioration of kidney function, or

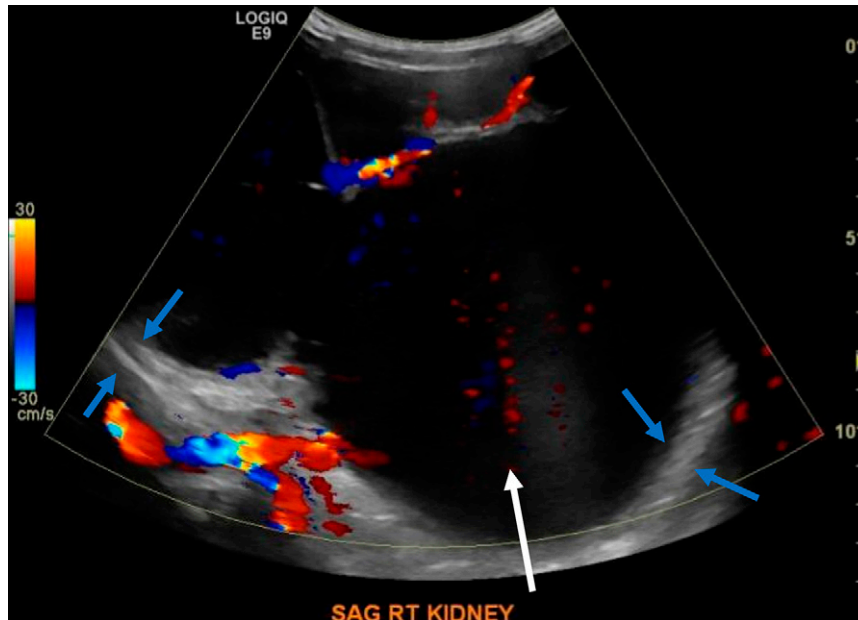


Figure 1. | The patient's abdominal ultrasound showing massive pelvocaliectasis of the right kidney. The white arrow indicates the massively dilated central collecting system surrounded by thinned kidney parenchyma, indicated by blue arrows in two areas. Sag, sagittal; Rt, right.

¹Department of Pediatrics, Louisiana State University Health Sciences Center, New Orleans, Louisiana

²Department of Radiology, Children's Hospital New Orleans, New Orleans, Louisiana

Correspondence: Dr. Jonathan Chawla, Department of Pediatrics, Louisiana State University Health Sciences Center, 200 Henry Clay Ave, New Orleans, LA 70118. Email: jschawla1991@gmail.com

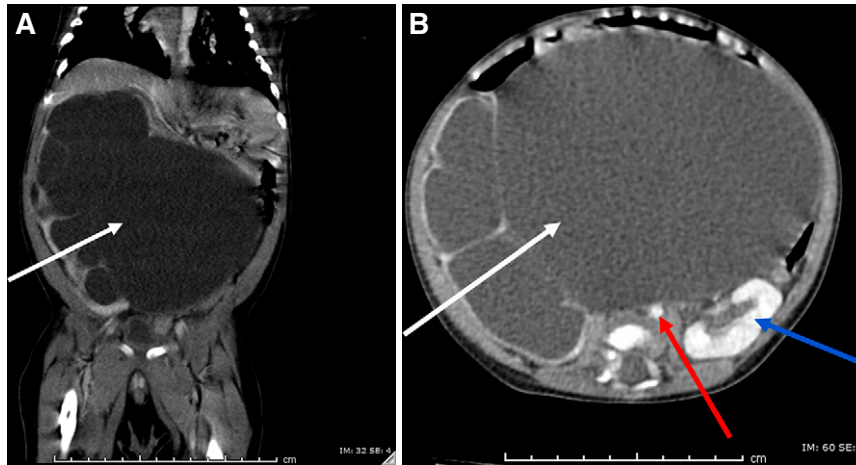


Figure 2. | Abdominal computed tomography (CT) scan shows massive hydronephrosis. (A) The patient's abdominal CT scan in the coronal plane showing the right kidney parenchyma stretched over the massively dilated central collecting system (white arrow), which occupies the majority of the abdomen. (B) The patient's abdominal computed tomography scan in the axial plane showing the right kidney parenchyma stretched over the massively dilated central collecting system (white arrow). There is a profound mass effect on abdominal organs, including the left kidney (blue arrow), vessels, and bowel, specifically compressing and displacing the aorta (red arrow) and inferior vena cava.

patients may develop an equilibrium state in which kidney function is preserved. If not caught on antenatal screening, infants with hydronephrosis secondary to UPJO may present with a palpable abdominal mass, urinary tract infection, hematuria, or failure to thrive. Acute kidney failure and hypertension are rare presentations, but are indications for prompt surgical intervention (decompression of collecting system with a nephrostomy tube) to prevent permanent injury and reduce BP (1,2). Patients with preserved kidney function can be treated conservatively and monitored with serial ultrasound and diuretic renography to assess function (3). Should patients who are initially asymptomatic with mild obstruction develop subacute symptoms—such as a decline in kidney function, stone formation, recurrent urinary tract infections, hypertension, or worsening obstructive drainage patterns on diuretic renography—they can become candidates for definitive correction with pyeloplasty. Chronic urinary tract obstruction can lead to tubular damage that can cause sodium wasting, nephrogenic diabetes insipidus, and hyperkalemic metabolic acidosis, the latter of which was noted in this case (4).

Teaching Points

- Congenital UPJO is the most common cause of antenatal hydronephrosis.
- Massive hydronephrosis due to UPJO may present with hypertensive crisis due to the mass effect on the renal vasculature.
- Urgent decompression of the collecting system is required in cases of hypertensive crisis and new-onset AKI.

Disclosures

All authors have nothing to disclose.

Funding

None.

Acknowledgments

Informed consent was obtained from the patient's immediate family.

Author Contributions

I. Ashoor was responsible for methodology and project administration; I. Ashoor and J. Chawla conceptualized the study; I. Ashoor, J. Chawla, and D. Manning were responsible for data curation; I. Ashoor and D. Manning reviewed and edited the manuscript; J. Chawla wrote the original draft; and D. Manning was responsible for software and visualization.

References

1. Al-Mashhadi A, Nevés T, Stenberg A, Karanikas B, Persson AE, Carlström M, Wåhlin N: Surgical treatment reduces blood pressure in children with unilateral congenital hydronephrosis. *J Pediatr Urol* 11: 91.e1–91.e6, 2015
2. de Waard D, Dik P, Lilien MR, Kok ET, de Jong TP: Hypertension is an indication for surgery in children with ureteropelvic junction obstruction. *J Urol* 179: 1976–1978; discussion 1978–1979, 2008
3. Ulman I, Jayanthi VR, Koff SA: The long-term followup of newborns with severe unilateral hydronephrosis initially treated nonoperatively. *J Urol* 164: 1101–1105, 2000
4. Becker A, Baum M: Obstructive uropathy. *Early Hum Dev* 82: 15–22, 2006

Received: June 2, 2020 Accepted: June 29, 2020